การผ่าตัดใส่ท่อยางในลำไส้เล็กของกระบือปลัก เพื่อใช้ในการศึกษาด้านโภชนศาสตร์

Surgical Implantation of Duodenal Catheter in Swamp Buffaloes for Nutritional Studies

โอภาส พิมพา[1] J.B. Liang[1] M.Y. Loqman[2] G.K. Mohd Azam Khan[2]
Opart Pimpa[1] J.B. Liang[1] M.Y. Loqman[2] G.K. Mohd Azam Khan[2]

บทคัดย่อ

กระบือปลักจำนวน 4 ตัว ได้รับการผ่าตัดเพื่อสอดสายยางพลาสติก (catheter) เข้าสู่ลำไส้เล็กส่วนต้น (duodenum) โดยสายยางดังกล่าวใช้เป็นท่อนำสารละลายพิวรีนเบส (purine bases) และอาหารเหลวอื่นๆ ที่ฉีดเข้าสู่ลำไส้เพื่อศึกษาการดูดซึมของสารละลายที่ลำไส้เล็ก จากการศึกษาการฉีดสารละลายพิวรีน ในอัตรา 2 ลิตร ต่อวันเข้าไปสู่ลำไส้เล็ก พบว่าการใช้สายยางนี้ไม่มีผลกระทบต่ออัตราการไหลของสารละลายที่ฉีดเข้าไป และไม่เกิดการอุดตันของท่อพลาสติกจากอาหารในลำไส้เล็กด้วย นอกจากนี้ยังไม่เกิดการรั่วไหลของสารละลายและอาหารจากส่วนลำไส้เล็ก ซึ่งในการผ่าตัดนี้พบว่าสัตว์สามารถฟื้นตัวกินอาหารได้ภายในเวลา 2 ชั่วโมงหลังการผ่าตัด และกลับเป็นปกติในช่วงเวลาประมาณ 1 อาทิตย์หลังการผ่าตัด

Abstract

Duodenum of four male swamp buffaloes were surgically cannulated with flexible plastic catheters. The small intestine catheter is a good tool for purine bases (PB) and other nutrients infusion. There was no infusion resistance or digesta flow blockage within and leakage of digesta from the catheter, when the animals were infused with 2 liters of PB solution per day. Most of animals began eating within 2 hours post operation and had normal appetite about 1 week after surgery.

คำสำคัญ: กระบือปลัก การผ่าตัด ท่อนำสารละลายเข้าสู่ลำไส้เล็ก การฉีดสารละลาย
Keywords: swamp buffalo, surgery, duodenal catheter, infusion

[1] Department of Animal Science, University Putra, Malaysia 43400 UPM Serdang, Malaysia
E-mail Opimpa@hotmail.com
[2] Department of Veterinary clinical studies, University Putra, Malaysia 43400 UPM Serdang, Malaysia

Introduction

Duodenally cannulated animals have been widely used for various nutritional studies in sheep (Balcells et al., 1991; Perez et al., 1996), cattle (McAllan, 1980; Kennedy et al., 1992) and buffaloes (Kennedy et al., 1992; Masoero et al., 1997). Common duodenal cannulas are either re-entrant or T-shape types. Ivan (1977) described the preparation of re-entrance cannula for sheep while the T-shape cannula for cattle and sheep were reported by Komarek (1981). Preparation of T-shape cannula for swamp buffalo had been described by Wanapat et al. (1994) and Pimpa et al. (1998).

The insertion of re-entrance and T-shape cannulas into the duodenum required a duodenal transection in order that the two cannulas could be drawn apart (Ivan, 1977; Komarek, 1981). Since the duodenal mesentery is very short, the procedure is very difficult (Ivan, 1977). In addition, the animals require special handling and care, they normally have a relatively short life span (Phillipson, 1952; Ash, 1962). Duodenal catheter is an alternative procedure to duodenal cannulation if it is used only for nutrient infusion into small intestine. Duodenal catheters are easier to insert and the technique has been successfully used for abomasal infusion in cattle (MacLeod et al., 1982). This paper describes the preparation of flexible duodenal catheters in swamp buffaloes which were recently used for the study of recovery rate of purine derivatives post infusion with various levels of purine into the small intestine (Pimpa et al., 2001).

Materials and Methods

Animal and catheter

Surgery were recently performed on 4 male swamp buffaloes *(Bubalus bubalis)*, (289 ± 19.80 kg) to study the trace recovery of urinary purine derivatives after PB infusion through duodenal catheter. The animals were kept in individual pen for 2 weeks before the surgery. The catheter was made from flexible plastic tube (40 cm long with a 4 mm. internal diameter). Each catheter had two flanges, the first flange (peritoneal flange, Fig. 1, a) was made from hard plastic to avoid catheter movement. The second flange (internal flange, Fig. 1, b) was located 10 cm apart from the first flange. This flange was made from the same material as the catheter. Each catheter had numerous pin point openings (Fig. 1, c) at its distal end to enable efficient dispersion of infused PB solution. A 2-3 cm slit beginning from the distal tip was also made along the length of the catheter to prevent its opening obstruction from digesta. The former catheter was fixed to the catheter using nylon string size zero while the latter was fixed to the catheter using parafilm.

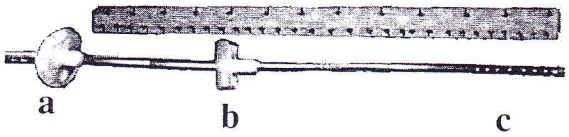

Figure 1. Duodenal catheter and associated components: (a) peritoneal flange, (b) internal flange, (c) numerous pin point openings

Surgery

Prior to the surgery, the animal was fasted for 36 hours and no water was given for the last 24 hours. The skin was washed, shaved, and aseptically prepared, using antiseptic solutions (chlorohexidine, alcohol and tincture iodine). Surgery was performed under sedation using xylazine (Romazine®, Jurox PTY. Ltd. Australia) given intramuscularly at 0.2 mg/kg body weight. Local anesthesia using inverted L-block technique was applied on the surgical site using 2% xylocaine. Surgery was performed while the animals either in standing or lateral recumbency position. Aseptic procedures were maintained throughout surgery. Skin incision was made either at the left mid paralumbar fossa region or at the left paracostal region. After the duodenum was isolated, the surrounding visceral organs were packed off with wet gauzes to prevent any contamination from the duodenal digesta spillage. Two stay sutures were placed at the two proposed end points of the duodenostomy site. Longitudinal incision was made with the length just enough to allow the insertion of the duodenal catheter (Fig. 2, a and b). The duodenostomy site was closed with purse string suture around the catheter by using 2/0 chromic catgut. The internal flange was secured to the serosal layer of the duodenum surface using the same suture material. The peritoneal flange was placed under the abdominal wall (Fig. 2, c). The external catheter end was exteriorized through a second skin incision made caudal to the first skin incision. The incision was closed as routine. Feed and water were given immediately after the surgery was completed. Normally the animals started eating within 2 hours post surgery.

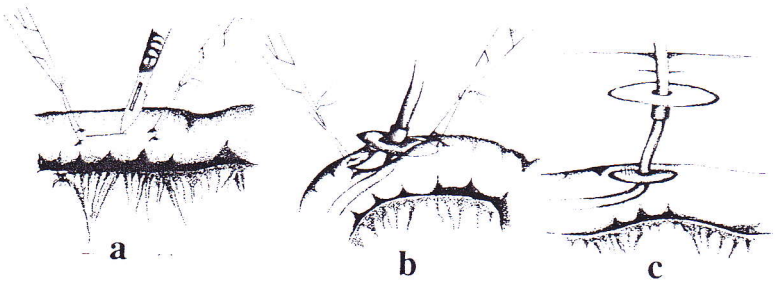

Figure 2. (a) A longitudinal duodenal incision (b) The catheter is inserted into the duodenum (c) The position of catheter and associated components inserted under the muscle layers.

Result and discussion

All the swamp buffaloes were successfully operated. They regained normal feed consumption 1 week after the surgery. Neither digesta leakage nor infection was evident in any buffalo. All buffaloes were kept in individual metabolism crates and fed at maintenance energy levels of 1% dry matter of body weight. Purine bases solution was infused continuously into the duodenum via a duodenal catheter using the multi-channel peristaltic pump at a rate of 2 liters per day (Fig. 3). They were successfully used in an experiment for a period of 37 days. Based on this study, duodenal catheter is a good tool for the studies requiring duodenal infusions.



Figure 3. Swamp buffaloes with duodenal catheters.

A major advantage of this catheter over the duodenal cannula was that it can be inserted quickly, easily and suitable for infusions. In addition, the duodenal cannula is a good tool for the duodenal digesta sampling and mobile bags insertion for digestion study. Duodenal cannula commonly remained functional for about 2 years while the duodenal catheter from this study remained functional only 3 months after experiment period. The duodenal catheter was specially prepared for PB infusion study for a short period purpose.

References

Ash, R.W. 1962. Gastro-intestinal reentrant cannulae for studies of digestion in sheep. Anim. Prod. 4:309-311.

Balcells, J., Guada, J.A., Castrillo, C. and Gasa, J. 1991. Urinary excretion of allantoin and allantoin precursors by sheep after different rates of purine infusion into the duodenum. J. Agric. Sci. Camb. 116:309-317.

Ivan, M. 1977. A new method for reentrant cannulation of the duodenum in sheep. Can. J. Anim. Sci. 57:225-227.

Kennedy, P.M., Boniface, A.N., Liang, Z.J., Muller, D. and Murray, R.M. 1992. Intake and digestion in swamp buffaloes and cattle. 2. The comparative response to urea supplements in animals fed tropical grasses. J. Agric. Sci. Camb. 119: 243-254.

Komerek, R.J. 1981. Intestinal cannulation of cattle and sheep with a T-shaped cannula designed for total digesta collection without externalizing digesta flow. J. Anim. Sci. 53: 796-802.

MacLeod, N.A., Corrigall, W., Stirton, R.A. and Ørskov, E.R. 1982. Intragastric infusion of nutrients in cattle. Br. J. Nutr. 47: 547-552.

Masoero, F., Cabiddu, A., Fiorentini, L., Moschini, M. and Piva, G. 1997. Effect of different energy content of diets on feed intestinal protein digestibility in buffaloes. Buffalo J. 3: 249-267.

McAllan, A.B. 1980. The degradation of nucleic acids in, and the removal of breakdown products from the small intestines of steers. Br. J. Nutr. 44:99-112.

Perez, J.F., Balcells, J., Guada, J.A. and Castrillo, C. 1996. Determination of rumen microbial-nitrogen production in sheep: a comparison of urinary purine excretion with methods using 15N and purine bases as markers of microbial-nitrogen entering the duodenum. Br. J. Nutr. 75:699-709.

Phillipson, A.T. 1952. The passage of digesta from the abomasum of sheep. J. Physiol. 116: 84.

Pimpa, O., Liang, J.B., Balcells, J., Jelan, Z.A. and Abdullah, N. 2001. Urinary purine derivatives excretion in swamp buffaloes post purine infusion into the duodenum. Anim. Feed Sci. Technol., in press.

Pimpa, O., Loqman, M.Y., Mohd Azam Khan, G.K., Khamseekhiew, B., Purwanto, B.P., Bengaly, K. and Liang, J.B., 1998. Proc. 20th MSAP Conf. Putrajaya, Malaysia.

Wanapat, M., Parker, D.S., Sommart, K., Kittiworawet, S. and Pimpa, O. 1994. Small intestinal cannulation of swamp buffalo for escape nutrient studies. Proc. 1st ABA. Thailand.